



Kinematics and Early Clinical Outcomes of Primary Total Knee Arthroplasty through a Lateral Subvastus Approach

Yves Vanderschelden¹, Alberto Grassi², Simone Bignozzi³, Irene Asmonti³, Stefano Zaffagnini²

¹Clinique côte d'Emeraude, St.Malo, FR

²Istituto Ortopedico Rizzoli, Bologna, IT

³Orthokey Italia srl, Firenze IT
igs.product@orthokey.eu

Abstract

A procedure with subvastus lateral approach has been utilized routinely on 60 patients, navigation was used due to the reduced exposure of this technique. Purpose of this study was to evaluate pain, function, and implant kinematics at early follow up of this surgical technique.

Tibial and femoral implant planning was based on ligament balance, gaps, and intraoperative kinematics. This approach, on pain and function, was verified at early follow-up. KSS and pain score were obtained at pre-op, 1, 3, 12 months. Data were analyzed with ANOVA for KSS and Chi-square for Pain.

No intraoperative complications were registered, no patellar tendon lesion or avulsion was noted. Preoperative average leg alignment was $4\pm 6^\circ$ varus (range 16; -14), corrected to 0° (range 2; -1). Kinematic analysis showed rollback on lateral compartment, while on medial compartment rollback was lower or negligible until 70° of flexion. Less than 5% had a “Fair” or “Poor” KSS score after 3 months. Preop pain was: 41% severe; 50% moderate; 8% mild and 0% none. At 1 month pain was: 2% severe; 18% moderate; 55% mild and 25% none. After 3 months 50% of patients had mild and 50% had no pain. This data was maintained after 1 year, with 31% of patients with mild and 69% of patients no pain ($p<0.05$).

This approach produced promising early outcomes in terms of pain, ROM and knee function, with less than 5% of patients presenting sub-optimal clinical results at 3-months. On symmetrical implant, medial pivot behavior was observed. Medial ligamental envelope preservation and navigated ligament balancing allow to optimize the medial stability and minimize the post-operative pain.

1 Introduction

Keywords (TKA, navigation, kinematic evaluation, lateral approach). Despite Total Knee Arthroplasty (TKA) design is aimed to replace the knee joint, surgical technique can play a significant role to obtain a joint kinematics as close as possible to the native, reducing pain at early follow-up and improving patients' recovery [1,2]. To this regard, keeping the antero-medial capsuloligamentous plan in continuity with the medial retinaculum, can improve quadriceps strength, medial pivot, optimize the medial stability and the extensor strength with the result of closely resemble the tibio-femoral behavior during knee flexion-extension, minimizing the post-operative pain. A lateral approach for computer assisted TKA was adopted for all patients, despite the initial knee varus or valgus deformity [3]. Purpose of this study is to evaluate pain, function, and implant kinematics at early follow up of this surgical technique.

2 Methods

60 consecutive patients (mean age 72.6 ± 8.0) underwent primary cruciate retaining TKA, with symmetrical condyles, through a lateral approach. Surgical approach includes the release of the lateral retinaculum, the lateral meniscus and half of the femoral insertion of fascia lata, with posterior cruciate ligament (PCL) retained. This allows medial subluxation of the patella, in particular with in a varus knee deformity. The quadriceps muscle remains intact and improves the lateral condyle mobility after TKA. Medial compartment stability and right strain of the PCL are obtained aiming at knee locking in full extension and a good roll back of the lateral femoral condyle during flexion. Surgery was performed with navigation system. Particular attention has been given to tibial and femoral implant planning based on ligament balance joint spaces and intra-operative kinematic throughout the range of motion. After implant fixation and before closure kinematics was repeated to register leg alignment, stability, and femoral implant rollback, defined as the nearest point of condylar surfaces over tibial resection. To verify the efficacy of surgical technique in reducing pain and function we focused at early follow up. The Knee Society Score (KSS) and pain score were obtained pre-operatively, at 1 month, at 3 months and 1 year post-operatively. Differences between controls were analyzed with ANOVA for KSS score and Chi-square for Pain score.

3 Results

No intraoperative complications registered; no patellar tendon lesion or avulsion noted. Postoperative complications were: one delayed wound tibial pins healing, two complex regional pain syndromes. Preoperative average leg alignment was $4 \pm 6^\circ$ varus (range 16 varus, 14 valgus), corrected to 0° (range 2 varus, 1 valgus) after surgery. After TKA implantation medial compartment stability was observed in all patients. Kinematic analysis showed rollback on lateral compartment for all patients, while on medial compartment rollback was lower or negligible in all patients, in flexion range 0° - 90° . Average femoral rollback of all patients is shown in figure 1.

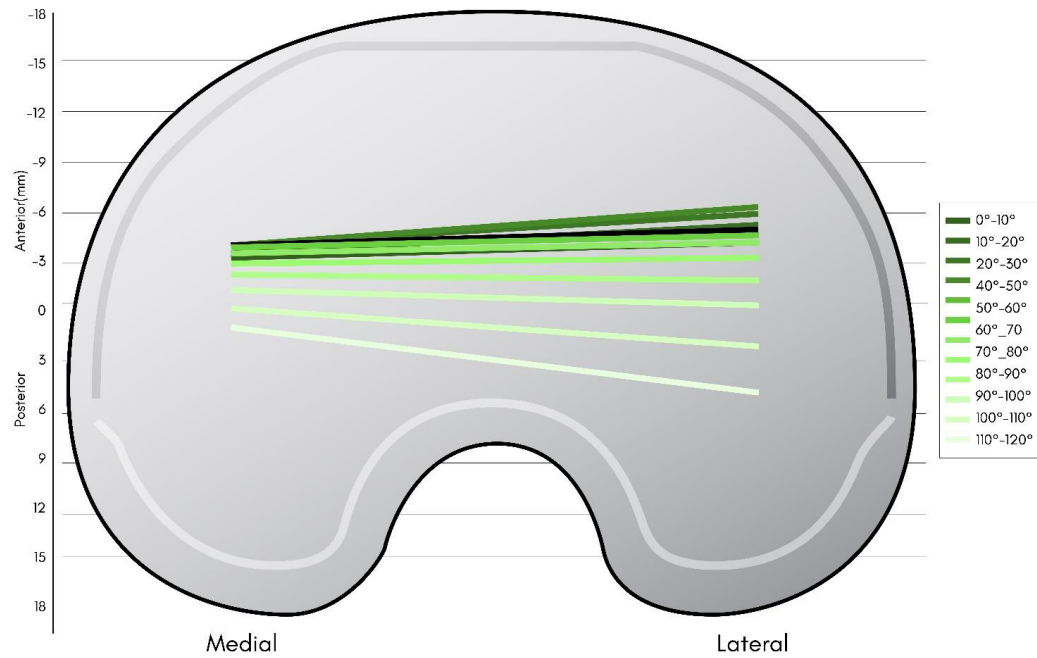


Figure 1: Medial and lateral contact point of femoral condyles over tibial plateau. Average results for all patients.

The KSS significantly improved from 108 ± 30 preoperatively to 155 ± 23 at 1 month, 179 ± 10 at 3 months and 189 ± 16 at 1 year ($p < 0.05$). Knee score is reported in figure 2.

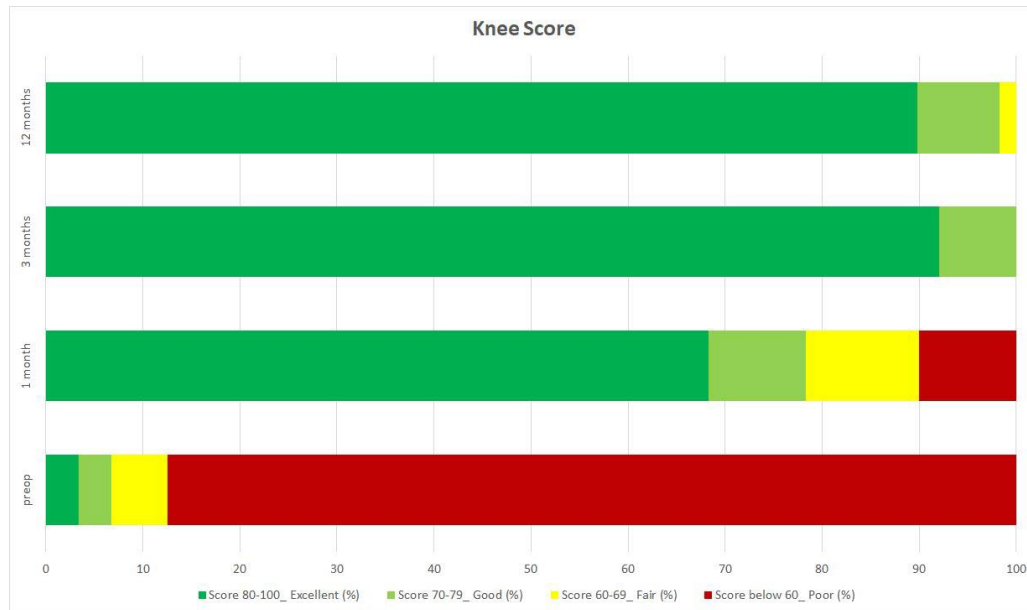


Figure 2: KSS knee score, divided in categories, at pre-op, 1, 3 and 12 months follow up.

Less than 5% had a “Fair” or “Poor” KSS score after 3 months. Preoperatively 41% of patients reported severe pain; 50% moderate; 8% mild and 0% none. After 1 month pain was as follows: 2% severe; 18% moderate; 55% mild and 25% none. After 3 months 50% of patients had mild and 50% had no pain. No patients reported moderate or severe pain. This data remained after 1 year, with 31% of patients with mild and 69% of patients no pain. No patients had moderate or severe pain ($p < 0.05$).

4 Discussion and Conclusion

(keywords; clinical scores, medial stability) TKA with lateral approach produced promising early outcomes in terms of pain, range of motion, and knee function, with only less than 5% of patients presenting sub-optimal clinical results after 3-month follow-up, compared to similar studies [4,5]. Despite the symmetrical implant design, medial compartment stability observed in all patients. Respecting the medial ligamental envelope and intense use of computer assisted ligament balancing allow to optimize the medial stability, the extensor strength and minimize the post-operative pain.

5 References

- [1] Petersen W, Rembitzki IV, Brüggemann GP, Ellermann A, Best R, Koppenburg AG, et al. Anterior knee pain after total knee arthroplasty: A narrative review. *Int Orthop* 2014.
- [2] Lee DH, Choi J, Nha KW, Kim HJ, Han SB. No difference in early functional outcomes for mini-midvastus and limited medial parapatellar approaches in navigation-assisted total knee arthroplasty: A prospective randomized clinical trial. *Knee Surg Sports Traumatol Arthrosc* 2011;19:66–73

[3] Lanting BA, Legault JA, Johnson MI, MacDonald SJ, Beveridge TS. Lateral subvastus approach: A cadaveric examination of its potential for total knee arthroplasty. *Knee* 2020;27:1271–8

[4] Rebal BA, Babatunde OM, Lee JH, Geller JA, Patrick DA, Macaulay W. Imageless computer navigation in total knee arthroplasty provides superior short term functional outcomes: A meta-analysis. *J Arthroplasty* 2014;29:938–44.

[5] Yaffe M, Luo M, Goyal N, Chan P, Patel A, Cayo M, et al. Clinical, functional, and radiographic outcomes following total knee arthroplasty with patient-specific instrumentation, computer-assisted surgery, and manual instrumentation: a short-term follow-up study. *Int J Comput Assist Radiol Surg* 2014;9:837–44